


ACUTE DYSPHAGIA UNDERLYING CANCER: TWO CLINICAL CASES



Altin Kuqo<sup>1,2</sup>, Aida Quka<sup>1</sup>, Oneda Cibuku<sup>1,2</sup>, Enver Halili<sup>1,2</sup>, Jera Kruja<sup>1,2</sup>

- 1. UHC Mother Teresa, Service of Neurology, Albania
- 2. University of Medicine, Faculty of Medicine, Albania

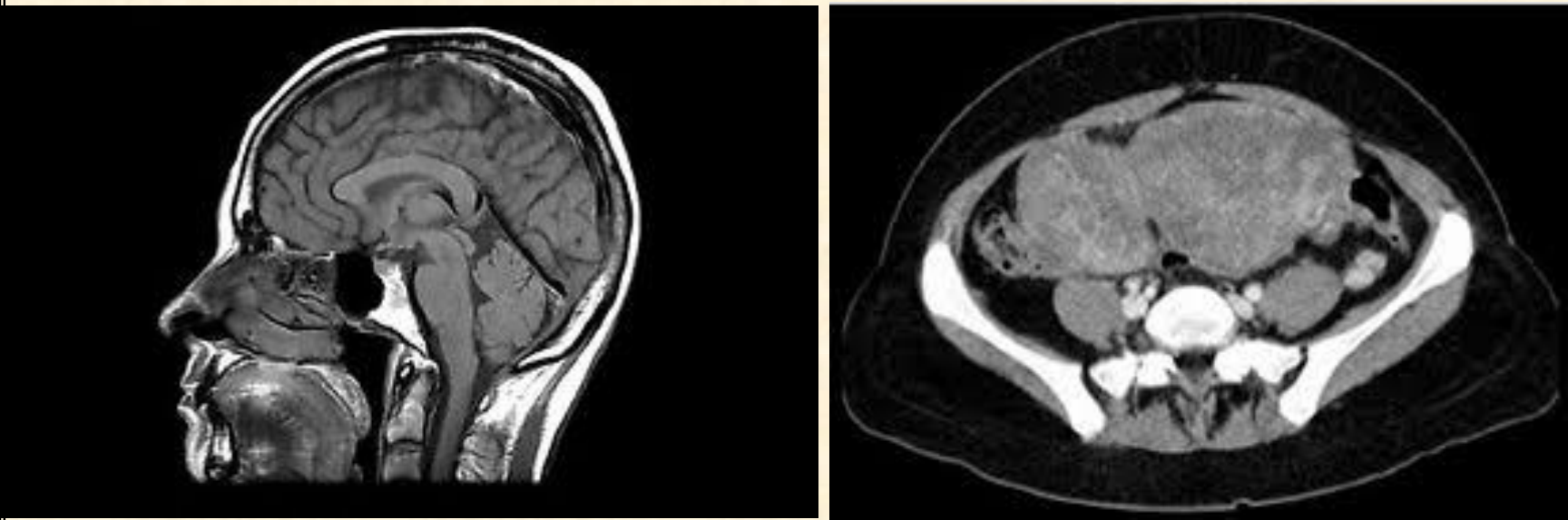


BACKGROUND

Acute dysphagia is a presenting symptom in many patients in the ER, more commonly associated to a stroke. But, it can be a presenting symptom of a paraneoplastic syndrome. We present two different clinical cases, with acute dysphagia as the first presenting symptom in the ER, later diagnosed with malignancies .

FIRST CLINICAL CASE

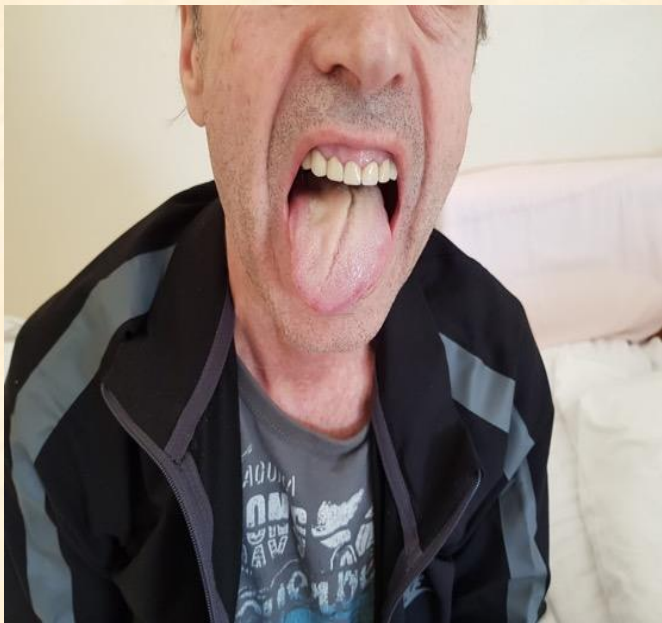A 54y old female, presenting with acute dysphagia in the ER. No past medical history. Normal brain CT scan. Diminished GAG reflex and mild gait ataxia. Brain MRI was normal. CA125, CA19.9 abnormally high. Total body CT scan revealed ovarian cancer. No metastasis in the CNS or other organs was present. After surgical resection of the cancer, there was visible improvement of dysphagia. Biopsy was compatible with ovarian adenocarcinoma.



Ca125 ↑↑  
Ca 19.9↑

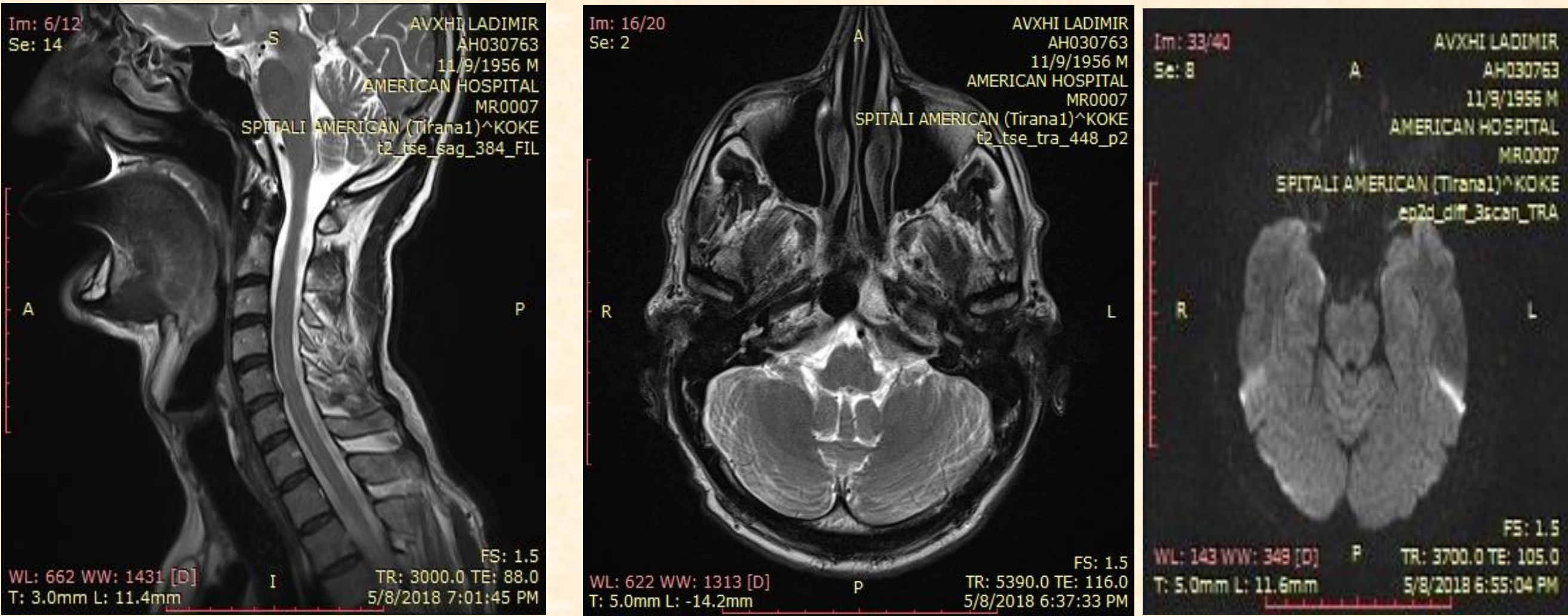
SECOND CLINICAL CASE

A 61y old male, with acute dysphagia starting the day prior to admission to the ER. He had diminished GAG reflex and a deviation of the tongue. His brain and cervical spine CT scan and MRI were normal. He referred weight loss 10 kg in the last 2 months and acid reflux. High CEA levels. A total body CT scan revealed thickening of the gastric walls. No metastasis in CNS or other organs were found. Biopsy showed gastric adenocarcinoma. Some improvement of dysphagia after surgery, but the pt died from complications during chemotherapy.

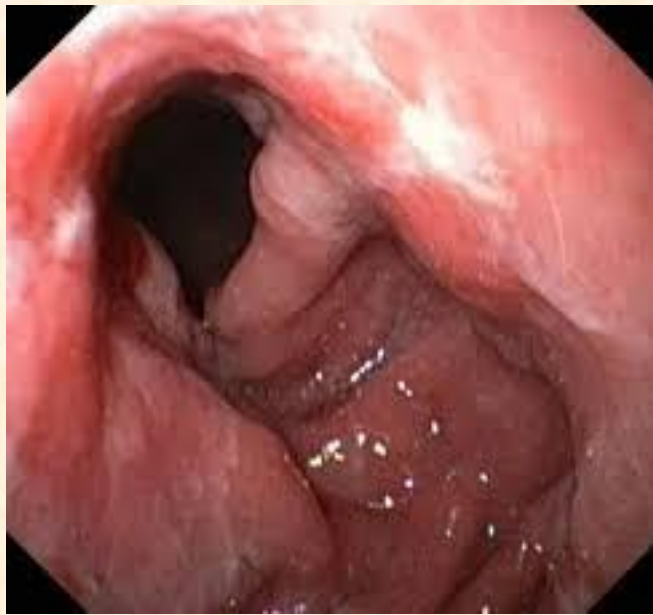


Deviation of the tongue

MRI IMAGES



CEA ↑



DISCUSSION

Dysphagia is a common symptom in the later stages of cancer. But, sometimes it can be part of the paraneoplastic syndrome, as an early and acute presenting symptom of a malignancy, even far away from the head or neck. For this reason, it is important to consider malignancies in the differential diagnosis in pt presenting in the ER with acute dysphagia. The mechanism underlying acute dysphagia, could be explained with the esophageal dismotility due to the paraneoplastic syndrome.