

Title: A Safer technique for bilateral suprascapular nerve (SN) denervation under fluoroscopy. Proposal: Lateral X Rays incidence of Scapula to confirm needle final position on SN (LS-SN).

Author: Juan Carlos Flores Prof Md Phd FIPP caidba.edu@gmail.com
 Director CAIDBA. Pain Center EPP Award. Buenos Aires, Argentina
 Chairman Latin American Section WIP

Objetives:

The safety of bilateral SN block and pulsed RF using LS-SN (Y view) was assessed. Many patients present bilateral pathology and risk of pneumothorax, and even the incidence is low, it affects the decision to perform a single stage procedure. Fig.1, 2

Methods:

Diagnostic blockage was assessed in 23 patients (11 bilateral and 12 unilateral) followed by pulsed RF of the suprascapular nerve confirmed by LS-SN to determine the distance between the pleura and the tip of the needle.

The technique requires 4 steps.

1. Prone position to visualize the suprascapular notch (open triangle in the lower vertex) with C Arm intensifier 35° cephalic and 35° ipsilateral oblique;
2. Advancing with curved needle tunnel vision until contact with the target is established and the patient feels the needle Fig 3, 4
3. Rotating the C arm to lateral of scapula moving the intensifier to contralateral oblique position in a PA view to visualize the scapula in strict profile, and essentially the tip of the needle and its distance from the pleura Fig 5

4. Stimulating, eventually moving or rotating the curved needle until obtaining appropriate sensory and motor responses followed by pulsed RF for 10 minutes.

Result:

Table 1 shows details of the treated population having observed effectiveness in the response to sensory and motor stimulation with RF to identify the SN and 0% incidence of pneumothorax in the uni or bilateral approach.

Conclusions:

LS-SN is as effective as other approaches to find the SN and is highly safe since the lung can be observed during needle manipulation. Also, the posterior view navigates with the needle tip far from other rami of the brachial plexus. Vascular puncture is the only minor risk which can be minimized by combining with US.

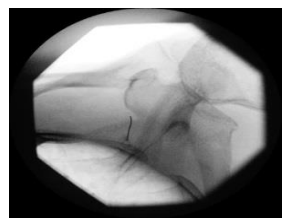
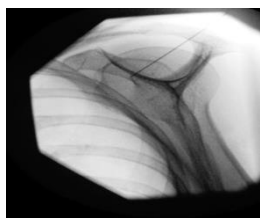
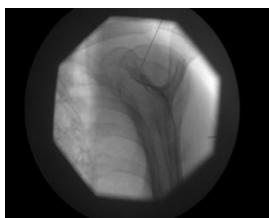


Fig 1, 2. Y view. Lateral of Scapula

Fig 3. PA view. C Arm intensifier 35° cephalic and 35° ipsilateral oblique.

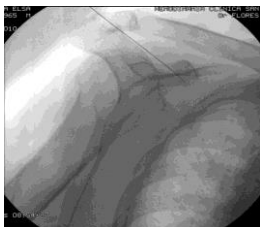
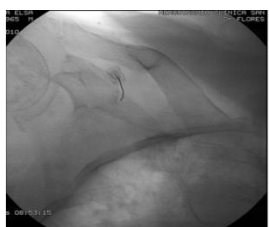

Fig 3, 4. PA view. C Arm intensifier 35° cephalic and 35° ipsilateral oblique.

Fig 5 (right). Y View. Lateral of Scapula to see the tip of needle close to the lung

Age	Sex	Pathology	S	T	Previous to pulsed RF, the sensory and motor stimulation with RF	N	Follow-up
77	M	Supraspinatus tear RCS	B	1	Ok	No	Relief physical therapy
84	F	Supraspinatus tear RCS Acromioclavicular arthrosis Cervical facets syndrome	B	7	Ok	No	Partial Relief Physical therapy pRF acromioclavicular joint
71	F	RCS Cervical facets	B	3	Ok	No	Relief
72	F	RCS Cervical facets and rheumatoid arthritis	U	1	Ok	No	Relief
83	F	RCS right Post-traumatic	U	1	Ok	No	Relief Drain Bursitis and pulsed RF of circumflex axillary nerve
75	F	RCS bilateral Bursitis and myofascial syndrome biceps	B	6	Ok	No	Relief Drain Bursitis PRP
48	M	RCS right	U	1	Ok	No	Relief
51	F	RCS right	U	4	Ok	No	Relief pRF the circumflex axillary nerve
69	F	Tendinitis supraspinatus Bilateral Arthrosis acromioclavicular	B	3	Ok	No	Relief PRP pRF circumflex axillary pRF intra joint acromioclavicular
66	F	RCS left	U	1	ok	No	Relief
84	M	RCS Bilateral Bursitis	B	4	ok	No	Relief Cardiac failure. COPD severe scoliosis
69	M	Bursitis and arthrosis acromioclavicular RCS right	U	2	ok	No	Relief pRF intraarticular acromioclavicular physical therapy
79	M	RCS right Bursitis Post-Fracture humerus	U	7	ok	No	Relief PRP
82	F	RCS Right	U	1	ok	No	Relief COPD severe. Breat cancer
47	M	Tendinitis and tear supraspinatus right	U	2	ok	No	Relief pRF Acromioclavicular intraarticular
62	F	RCS Left Bursitis	U	1	ok	No	Relief Drain bursitis Colon Cancer
62	F	RCS bilateral glenohumeral arthritis and atrophy muscle of biceps	B	14	ok	No	Relief PRP, RIT Physical therapy
61	M	RCS right post-traumatic	U	1	ok	No	Relief Physical therapy
90	F	RCS right	U	7	ok	No	Moderate relief
65	M	RCS bilateral post traumatic Electric shock	B	2	Ok	No	Relief PRP
63	F	RCS bilateral Post Stroke	B	1	Ok	No	Relief Physical therapy
66	F	Bursitis subacromial y subdeltoidea Tendinitis supraespinosa	B	5	Ok	No	Relief Physical therapy
49	F	RCS bilateral bursitis supraspinatus tear post-traumatic	B	2	Ok	No	Relief Physical therapy and pRF circumflex axillary nerve

Table 1. Pulsed Rf of suprascapular nerve. M: Male; F: Female; RCS: rotator cuff syndrome; S: Side; U: Unilateral, B: Bilateral; T: Time of evolution in years; N: Neumothorax; PRP: plasma rich platelet; RIT: regenerative inyection therapy

Keywords: Suprascapular nerve block; neumothorax risk; bilateral rotator cuff syndrome; supraspinatus tear; pulsed radiofrequency.

Institutional Ethics and Informed Consent Criteria prior to block and RF satisfied in every case.